Left ventricle

Left ventricle (Size)								
	Male				Female			
	Normal range	Mildly abnormal	Moderately abnormal	Severely abnormal	Normal range	Mildly abnormal	Moderately abnormal	Severely abnormal
LVIDd (cm) Left ventricular internal dimension at end-diastole	4,2 - 5,8	5,9 - 6,3	6,4 - 6,8	>6,8	3,8 - 5,2	5,3 - 5,6	5,7 - 6,1	>6,1
LVIDd (cm/m2) Left ventricular internal dimension at end-diastole	2,2 - 3,0	3,1 - 3,3	3,4 - 3,6	>3,6	2,3 - 3,1	3,2 - 3,4	3,5 - 3,7	>3,7
LVIDs (cm) Left ventricular internal dimension at end-systole	2,5 - 4,0	4,1 - 4,3	4,4 - 4,5	>4,5	2,2 - 3,5	3,6 - 3,8	3,9 - 4,1	>4,1
LVIDs (cm/m2) Left ventricular internal dimension at end-systole	1,3 - 2,1	2,2 - 2,3	2,4 - 2,5	>2,5	1,3 - 2,1	2,2 - 2,3	2,4 - 2,6	>2,6
IVSd (cm) Interventricular septum thickness at end-diastole	0,6 - 1,0	1,1 - 1,3	1,4 - 1,6	>1,6	0,6 - 0,9	1,0 - 1,2	1,3 - 1,5	>1,5
PWd (cm) Left ventricular posterior wall thickness at end-diastole	0,6 - 1,0	1,1 - 1,3	1,4 - 1,6	>1,6	0,6 - 0,9	1,0 - 1,2	1,3 - 1,5	>1,5
RWT Relative wall thickness	0,24 - 0,42	0,43 - 0,46	0,47 - 0,51	>0,52	0,22 - 0,42	0,43 - 0,47	0,48 - 0,52	>0,53

Recommendations for Cardiac Chamber Quantification by Echocardiography in Adults: An Update from the ASE and EACVI (2015)

👉 Free Online ECG Book

Left ventricle (Mass)

	Male				Female			
	Normal range	Mildly abnormal	Moderately abnormal	Severely abnormal	Normal range	Mildly abnormal	Moderately abnormal	Severely abnormal
LV mass (g) Left ventricular mass	88 - 224	225 - 258	259 - 292	>292	67 - 162	163 - 186	187 - 210	>210
LV mass (g/m2) Left ventricular mass	49 - 115	116 - 131	132 - 148	>148	43 - 95	96 - 108	109 - 121	>121

Recommendations for Cardiac Chamber Quantification by Echocardiography in Adults: An Update from the ASE and EACVI (2015)

Left ventricle (Volume)

	Male				Female			
	Normal range	Mildly abnormal	Moderately abnormal	Severely abnormal	Normal range	Mildly abnormal	Moderately abnormal	Severely abnormal
LVEDV (ml) Left ventricular end-diastole volume (Biplane)	62 - 150	151 - 174	175 - 200	>200	46 - 106	107 - 120	121 - 130	>130
LVEDV (ml/m2) Left ventricular end-diastole volume (Biplane)	34 - 74	75 - 89	90 - 100	>100	29 - 61	62 - 70	71 - 80	>80
LVESV (ml) Left ventricular end-systole volume (Biplane)	21 - 61	62 - 73	74 - 85	>85	14 - 42	43 - 55	56 - 67	>67
LVESV (ml/m2) Left ventricular end-systole volume (Biplane)	11 - 31	32 - 38	39 - 45	>45	8 - 24	25 - 32	33 - 40	>40

Recommendations for Cardiac Chamber Quantification by Echocardiography in Adults: An Update from the ASE and EACVI (2015)

Left ventricle (Ejection fraction)

	Male				Female			
	Normal range	Mildly abnormal	Moderately abnormal	Severely abnormal	Normal range	Mildly abnormal	Moderately abnormal	Severely abnormal
LV EF (%) Left ventricular ejection fraction (Biplane)	52 - 72	41 - 51	30 - 40	<30	54 - 74	41 - 53	30 - 40	<30

Recommendations for Cardiac Chamber Quantification by Echocardiography in Adults: An Update from the ASE and EACVI (2015)

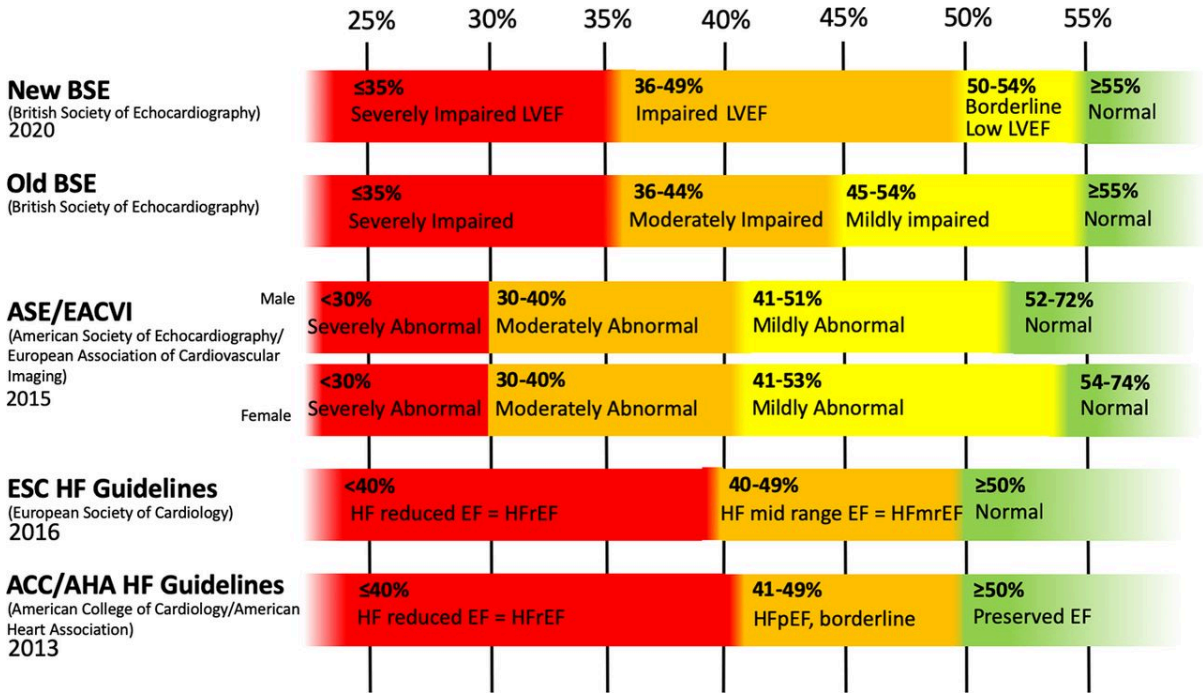

What is 'normal' left ventricular ejection fraction? (heart.bmj.com)

Left ventricle (Geometry)			
	LV mass(g/m^2) Left ventricular mass		RWT Relative wall thickness
Normal left ventricle	≤115 (Male)	≤95 (Female)	<0,42
Concentric hypertrophy	>115 (Male)	>95 (Female)	>0,42
Eccentric hypertrophy	>115 (Male)	>95 (Female)	<0,42
Concentric remodeling	≤115 (Male)	≤95 (Female)	>0,42

Description of LV geometry, using at the minimum the four categories of normal geometry, concentric remodelling, and concentric and eccentric hypertrophy, should be a standard component of the echocardiography report.

Recommendations on the use of echocardiography in adult hypertension: a report from the EACVI and the ASE (2015)

Left ventricle (Geometry)

	LVEDV(ml/m^2) Left ventricular end-diastole volume (Biplane)	LV mass(g/m^2) Left ventricular mass		RWT Relative wall thickness
Normal left ventricle	≤75	≤115 (Male)	≤95 (Female)	0,32-0,42
Physiological hypertrophy	>75	>115 (Male)	>95 (Female)	0,32-0,42
Concentric remodeling	≤75	≤115 (Male)	≤95 (Female)	>0,42
Eccentric remodelling	>75	≤115 (Male)	≤95 (Female)	<0,32
Concentric hypertrophy	≤75	>115 (Male)	>95 (Female)	>0,42
Mixed hypertrophy	>75	>115 (Male)	>95 (Female)	>0,42
Dilated hypertrophy	>75	>115 (Male)	>95 (Female)	0,32-0,42
Eccentric hypertrophy	>75	>115 (Male)	>95 (Female)	<0,32

Recommendations on the use of echocardiography in adult hypertension: a report from the EACVI and the ASE (2015)

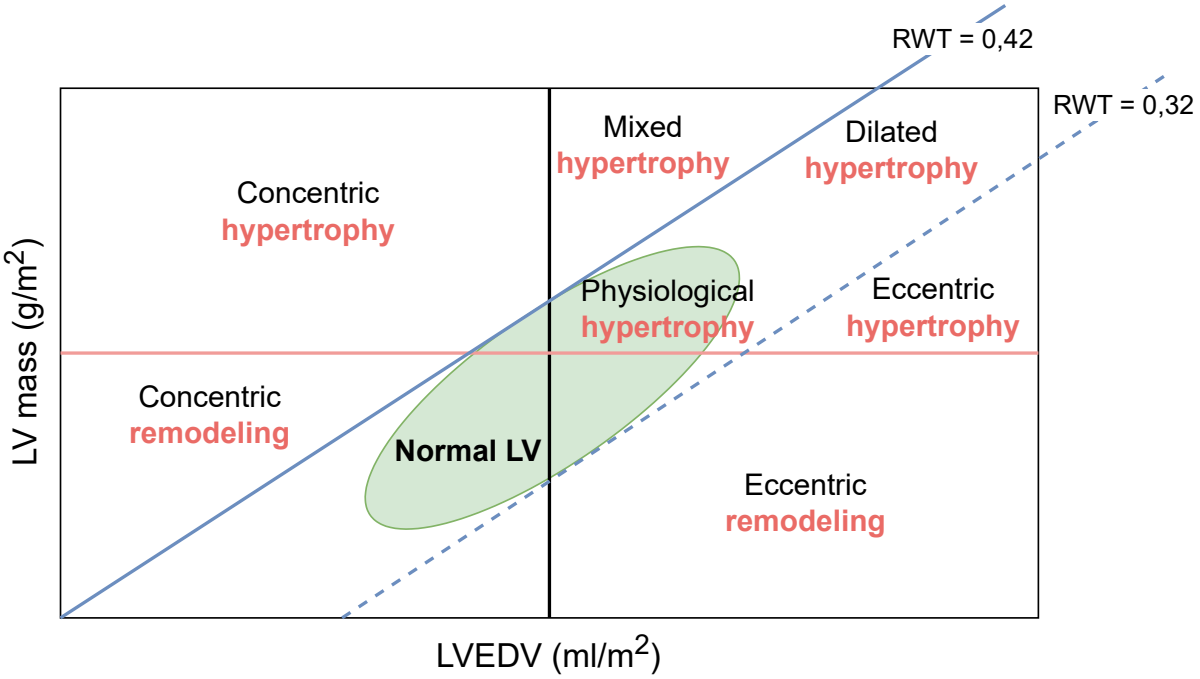

- The red horizontal line separates LV hypertrophy from normal LV mass.
- The black vertical line separates dilated from nondilated ventricles.
- The two oblique blue lines delimit the upper (0.42) and lower (0.32) limit of normal RWT.
- This leads to eight categories of ventricles.
- The green ellipse indicates the area of normal ventricles including physiological LV enlargement.

Recommendations on the use of echocardiography in adult hypertension: a report from the EACVI and the ASE (2015)

Left ventricular diastolic function

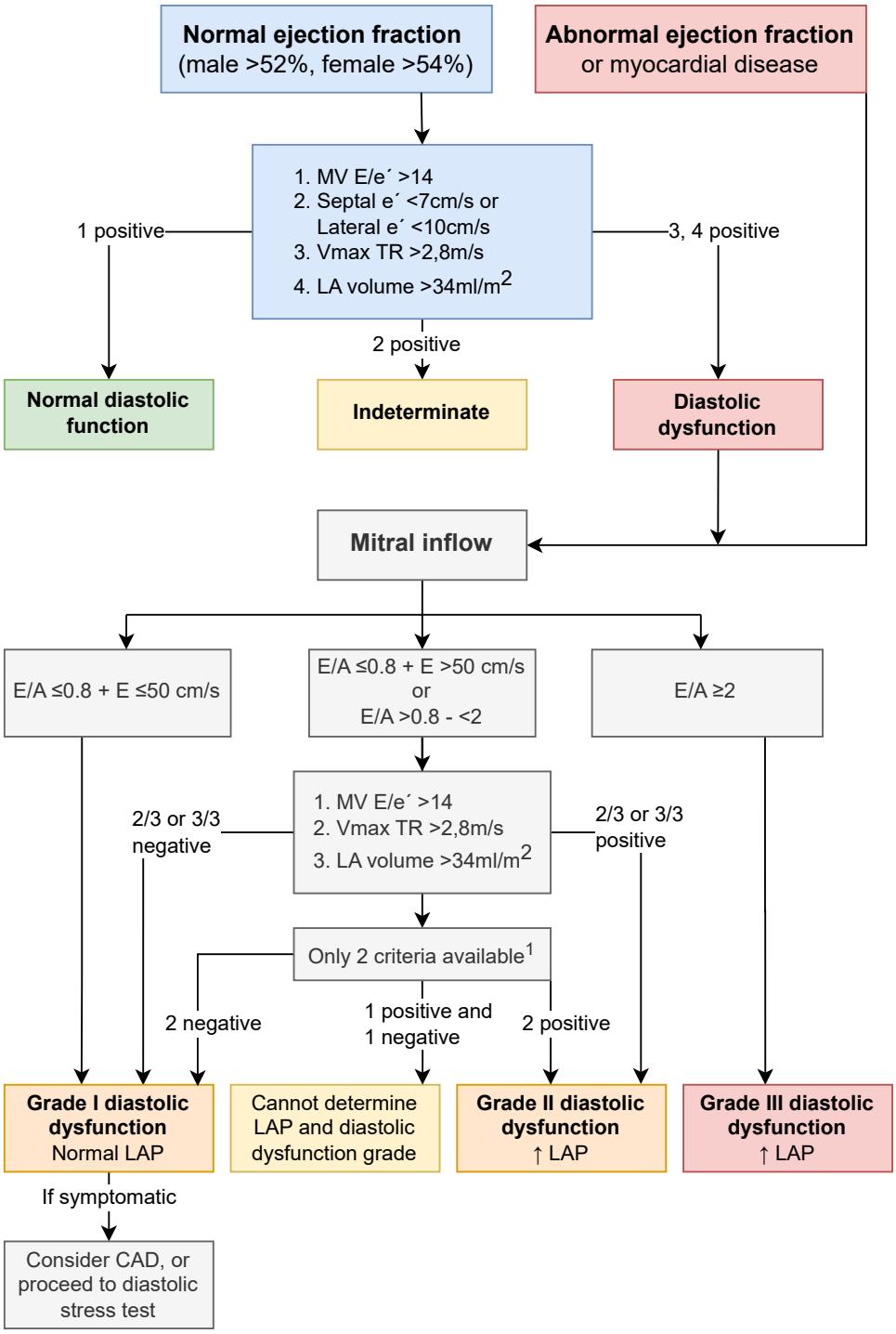

1. LAP indeterminate if only 1 of 3 parameters available. Pulmonary vein S/D ratio <1 applicable to conclude elevated LAP in patients with depressed LV EF.

Recommendations for the Evaluation of LV Diastolic Function by Echocardiography: An Update from the ASE and EACVI (2016)

Assessment of LV filling pressures in special populations	
Disease	**Echocardiographic measurements and cutoff values**
Atrial fibrillation	Peak acceleration rate of mitral E velocity (≥1,900 cm/sec ^{2}) IVRT (≤65 msec) DT of pulmonary venous diastolic velocity (≤220 msec) E/Vp ratio (≥1.4) Septal E/e´ ratio (≥11)
Sinus tachycardia	Mitral inflow pattern with predominant early LV filling in patients with EFs <50% IVRT ≤70 msec is specific (79%) Pulmonary vein systolic filling fraction ≤40% is specific (88%) Average E/e´ >14 (this cutoff has highest specificity but low sensitivity) When E and A velocities are partially or completely fused, the presence of a compensatory period after premature beats often leads to separation of E and A velocities which can be used for assessment of diastolic function
Hypertrophic cardiomyopathy	Average E/e´ (>14) Ar-A (≥30 msec) TR peak velocity (>2.8 m/sec) LA volume (>34 mL/m2).
Restrictive cardiomyopathy	DT (<140 msec) Mitral E/A (>2.5) IVRT (<50 msec has high specificity) Average E/e´ (>14)
Noncardiac pulmonary hypertension	Lateral E/e´ can be applied to determine whether a cardiac etiology is the underlying reason for the increased pulmonary artery pressures When cardiac etiology is present, lateral E/e´ is >13, whereas in patients with pulmonary hypertension due to a noncardiac etiology, lateral E/e´ is <8
Mitral stenosis	IVRT (<60 msec has high specificity) IVRT/$T_{E\text{-}e'}$ (<4.2) Mitral A velocity (>1.5 m/sec)
Mitral regurgitation	Ar-A (≥30 msec) IVRT (<60 msec has high specificity) IVRT/$T_{E\text{-}e'}$ (<5.6) may be applied for the prediction of LV filling pressures in patients with MR and normal EFs Average E/e´ (>14) may be considered only in patients with depressed EFs

Recommendations for the Evaluation of LV Diastolic Function by Echocardiography: An Update from the ASE and EACVI (2016)

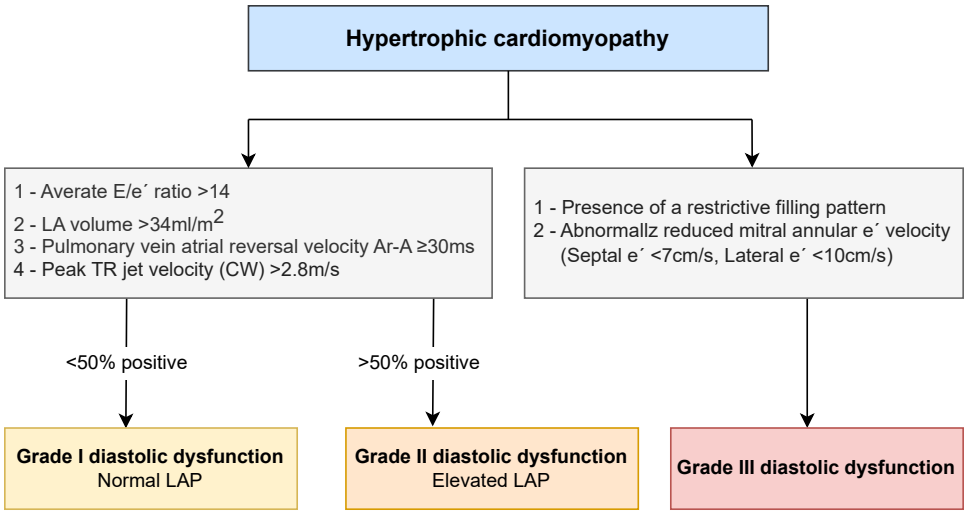
Hypertrophic cardiomyopathy
1 - Averate E/e´ ratio >14
2 - LA volume >34ml/m2
3 - Pulmonary vein atrial reversal velocity Ar-A ≥30ms
4 - Peak TR jet velocity (CW) >2.8m/s
1 - Presence of a restrictive filling pattern
2 - Abnormallz reduced mitral annular e´ velocity (Septal e´ <7cm/s, Lateral e´ <10cm/s)
<50% positive
>50% positive
Grade I diastolic dysfunction
Normal LAP
Grade II diastolic dysfunction
Elevated LAP
Grade III diastolic dysfunction

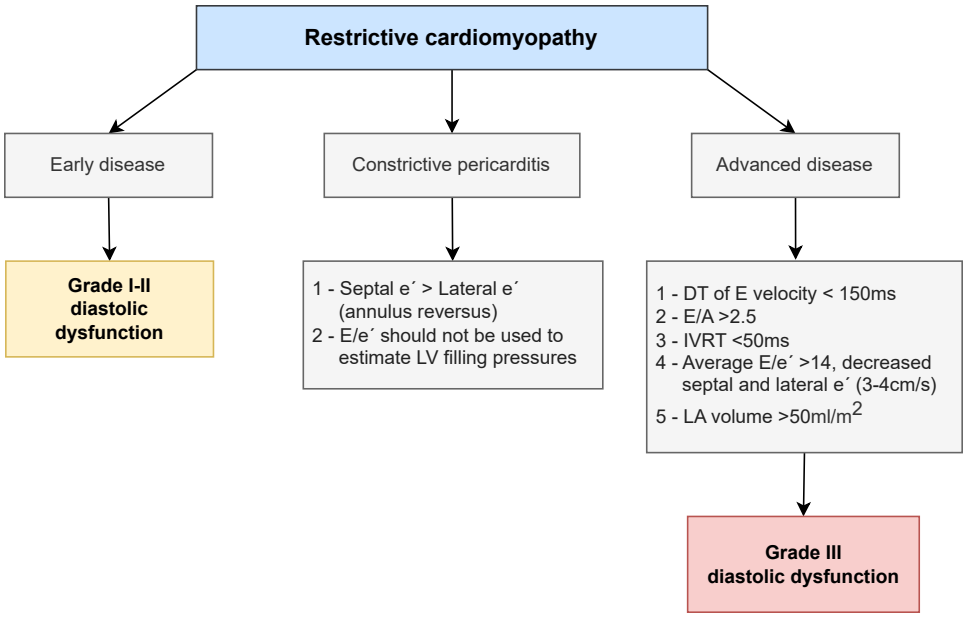
Restrictive cardiomyopathy
Early disease
Constrictive pericarditis
Advanced disease
Grade I-II diastolic dysfunction
1 - Septal e´ > Lateral e´ (annulus reversus)
2 - E/e´ should not be used to estimate LV filling pressures
1 - DT of E velocity < 150ms
2 - E/A >2.5
3 - IVRT <50ms
4 - Average E/e´ >14, decreased septal and lateral e´ (3-4cm/s)
5 - LA volume >50ml/m2
Grade III diastolic dysfunction

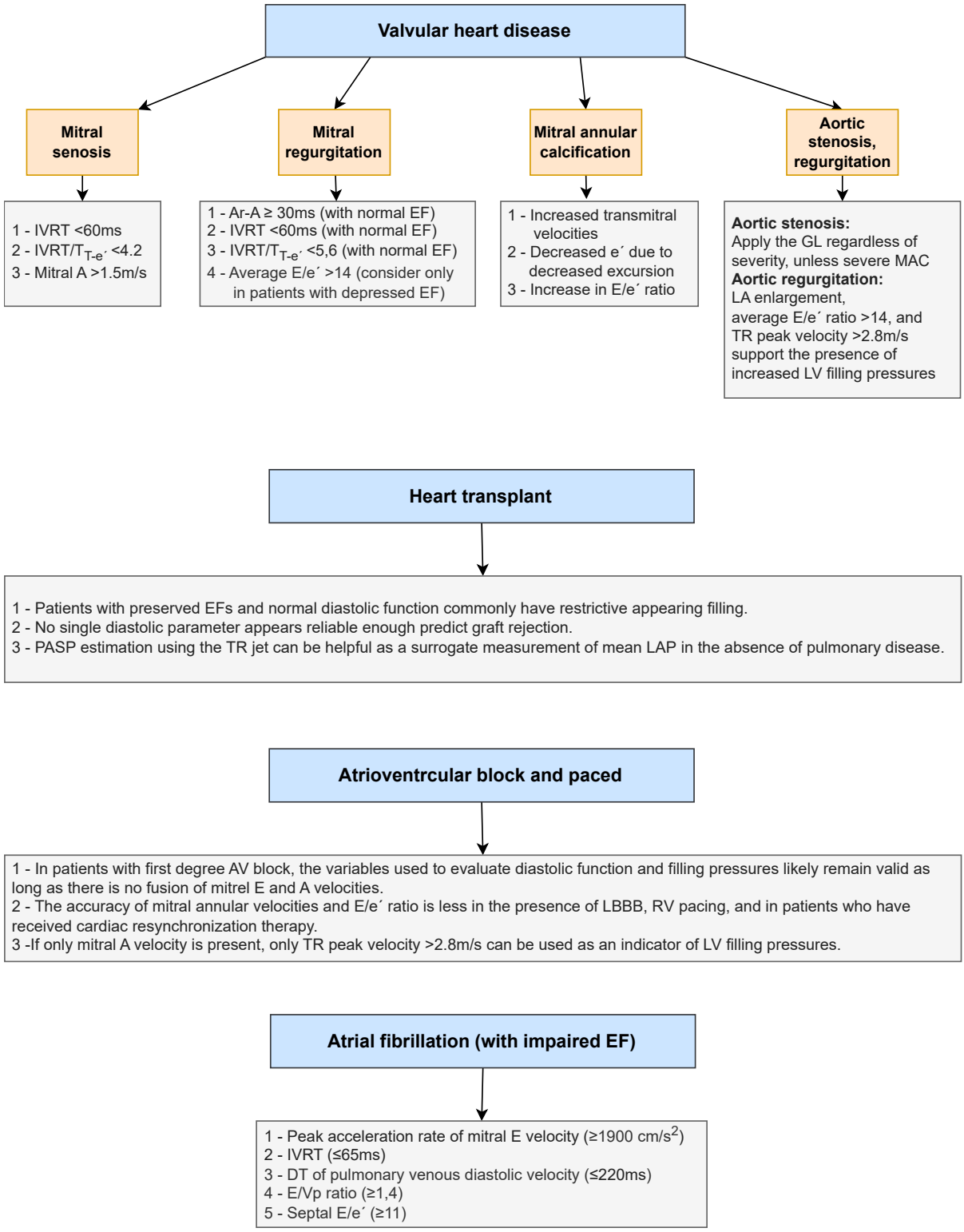

Recommendations for the Evaluation of LV Diastolic Function by Echocardiography: An Update from the ASE and EACVI (2016)
ASE recommendations for the evaluation of LV diastolic function by echocardiography: Quick reference (2016)

Right ventricle

Right ventricle (Size)	
$RVD1_{basal}$ Right ventricular basal diameter at end-diastole	25 - 41mm
$RVD2_{mid}$ Right ventricular mid diameter at end-diastole	19 - 35mm
$RVD3_{long}$ Right ventricular longitudinal diameter at end-diastole	59 - 83mm
$RVOT_{prox(PLAX)}$ Right ventricular outflow tract at proximal (PLAX)	20 - 30mm
$RVOT_{prox(PSAX)}$ Right ventricular outflow tract at proximal (PSAX)	21 - 35mm
$RVOT_{distal(PSAX)}$ Right ventricular outflow tract at distal (PSAX)	17 - 27mm
$PA_{diameter}$ Main pulmonary artery diameter	15 - 25mm
RVWT Right ventricular wall thickness	1 - 5mm

Guidelines for the Echocardiographic Assessment of the Right Heart in Adults: ASE, EACVI, ESC, CSE (2010)
Recommendations for Cardiac Chamber Quantification by Echocardiography in Adults: An Update from the ASE and EACVI (2015)
Guidelines for the diagnosis and management of acute pulmonary embolism ESC, ERS (2019)

Right ventricle (Area, Volume)		
	Male	**Female**
RV EDA (cm^2) Right ventricular end-diastolic area	10 - 24	8 - 20
RV EDA (cm^2/m^2) Right ventricular end-diastolic area	5 - 12,6	4,5 - 11,5
RV ESA (cm^2) Right ventricular end-systolic area	3 - 15	3 - 11
RV ESA (cm^2/m^2) Right ventricular end-systolic area	2 - 7,4	1,6 - 6,4
RV EDV (ml/m^2) Right ventricular end-diastolic volume	35 - 87	32 - 74
RV ESV (ml/m^2) Right ventricular end-systolic volume	10 - 44	8 - 36

Right ventricle (Function)	
Variable	**Abnormal**
TAPSE Tricuspid annular plane systolic excursion	<17mm
S' $Wave_{pulsedTDI}$ Peak systolic velocity tricuspid annulus (Pulsed TDI)	<9,5cm/s
S' $Wave_{colorTDI}$ Peak systolic velocity tricuspid annulus (Color TDI)	<6cm/s
FAC Fractional Area Change	<35%
RV EF Right ventricular ejection fraction	<45%
$RIMP_{TDI}$ Right Ventricular Index of Myocardial Performance (TDI)	>0,54
$RIMP_{PWd}$ Right Ventricular Index of Myocardial Performance (PWd)	>0,43
IVA_{RV} Myocardial acceleration during isovolumic contraction	<1,1m/s^2
PVR Pulmonary vascular ressistance	>3WU
RV dP/dt Rate of rise of right ventricle pressure	<400mmHg/s
E/A_{TrV} Tricuspid valve E / A wave ratio	<0,8 >2
DT TrV Tricuspid valve deceleration time	<119ms >242ms
e´ $wave_{TrV}$ eak velocity in early diastole of tricuspid annulus (TDI)	<7,8cm/s
$e´/a´_{TrV}$ Tricuspid valve e´ / a´ ratio (TDI)	<0,52
$E/e´_{TrV}$ Tricuspid valve E / e´ ratio	>6
PAAT Pulmonary artery acceleration time	<100ms

Guidelines for the Echocardiographic Assessment of the Right Heart in Adults: ASE, EACVI, ESC, CSE (2010)
Recommendations for Cardiac Chamber Quantification by Echocardiography in Adults: An Update from the ASE and EACVI (2015)
Guidelines for the diagnosis and management of acute pulmonary embolism ESC, ERS (2019)

Right ventricle (Pressure)	
Variable	**Abnormal**
RVSP$_{(SPAP)}$ Right ventricular systolic pressure	>35mmHg
mPAP Mean pulmonar arterial pressure	>25mmHg
PADP Pulmonary artery diastolic pressure	>15mmHg

Guidelines for the Echocardiographic Assessment of the Right Heart in Adults: ASE, EACVI, ESC, CSE (2010)

Right ventricle (Pressure overload)	
Variable	**Abnormal**
RVOT$_{prox(PLAX)}$ Right ventricular outflow tract at proximal (PLAX)	>30mm
Basal RV/LV Basal right/left ventricle ratio	>1
D septum D shaped septum	Yes
IVC$_{diameter}$ Inferior vena cava diameter	>2,1cm
IVC$_{collaps}$ Inferior vena cava collapsibility	<50%
60/60 sign 60/60 Echo sign	Yes
McConnel´s sign Mid wall hypokinesia and apical hyperkinesia	Yes
Trombus RV Right heart mobile trombus	Yes
TAPSE Tricuspid annular plane systolic excursion	<16mm
S' wave$_{pulsedTDI}$ Peak systolic velocity tricuspid annulus (Pulsed TDI)	<9,5cm/s

Regional wall motion abnormality and segments

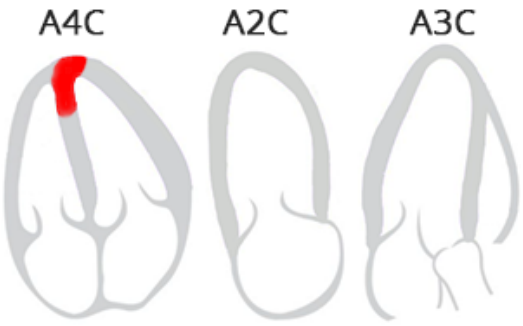

Distal septum infarct

- LAD (distal, mid., prox.)
- Low remodeling risk
- A4C, A2C, A3C (Echo views)

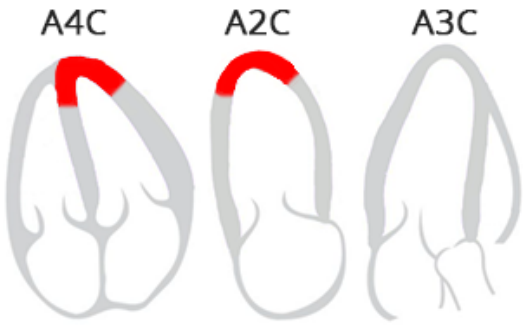

Supraapical infarct

- LAD (distal, mid., prox.)
- Small supraapical aneurysm
- Low remodeling risk

Supraapical and distal septal infarcts can also occur in proximal LAD occlusion after rapid reperfusion.

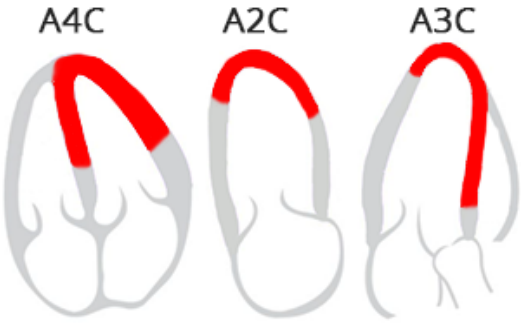

Proximal LAD type AMI

- LAD (before 1st septal branch, left main)
- Always remodeling
- Poor prognosis

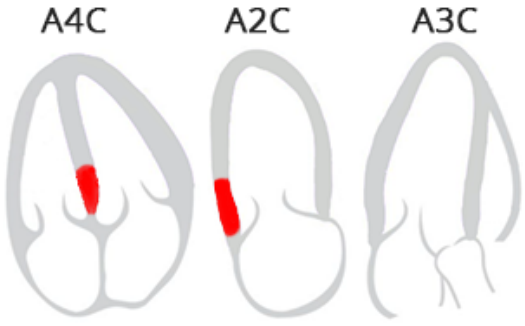

Small basal inferior infarct

- RCA
- Difficult region to interpret
- Low remodeling risk

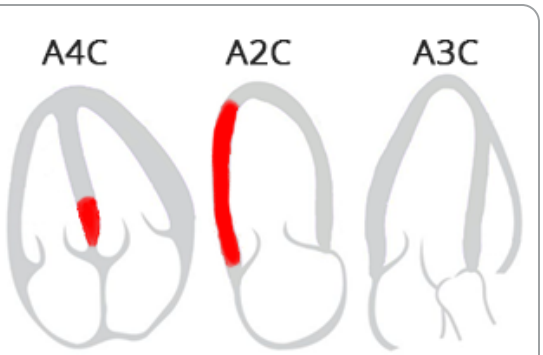

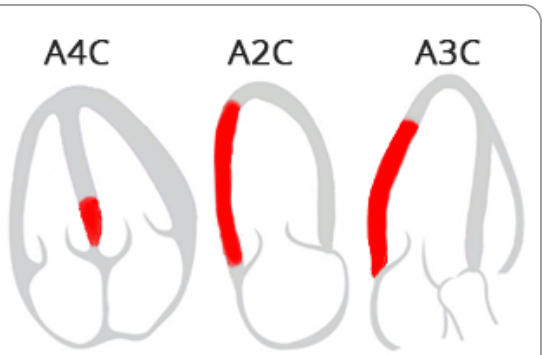

Inferior Infarct

- RCA
- Low-moderate remodeling risk

Infero-Posterior Infarct

- RCA (dominant) or Cx (large, prox.)
- Moderate remodeling risk
- Inferolateral (also called posterior)

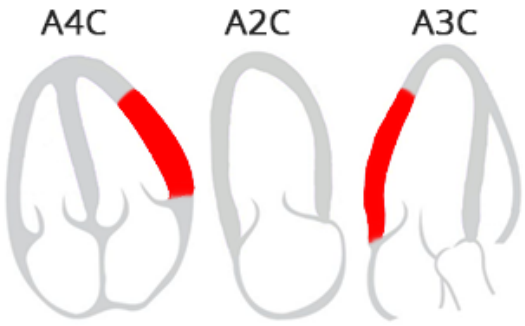

Posterolateral Infarct

- CX, RCA
- Moderate remodeling risk
- Inferolateral (also called posterior)

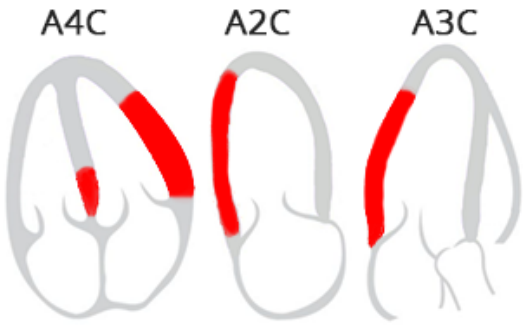

Infero-Posterior-Lateral Infarct

- Dominant RCA, CX (large, prox.)
- High remodeling risk
- Inferolateral (also called posterior)

Inferior/ posterior/ postero-lateral infarcts pose an elevated risk for restrictive MR!

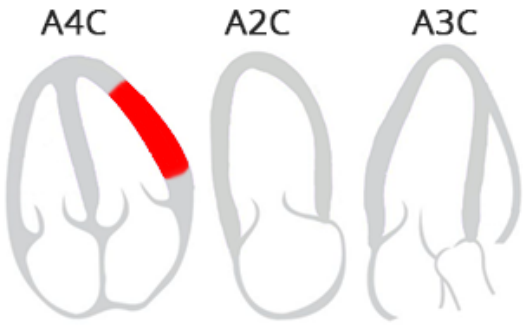

Lateral Infarct

- CX, LAD (diagonal branch, difficult to interpret)
- Low remodeling risk

- When assessing the patterns of myocardial infarction, always consider the possibility of multiple/sequential infarcts!

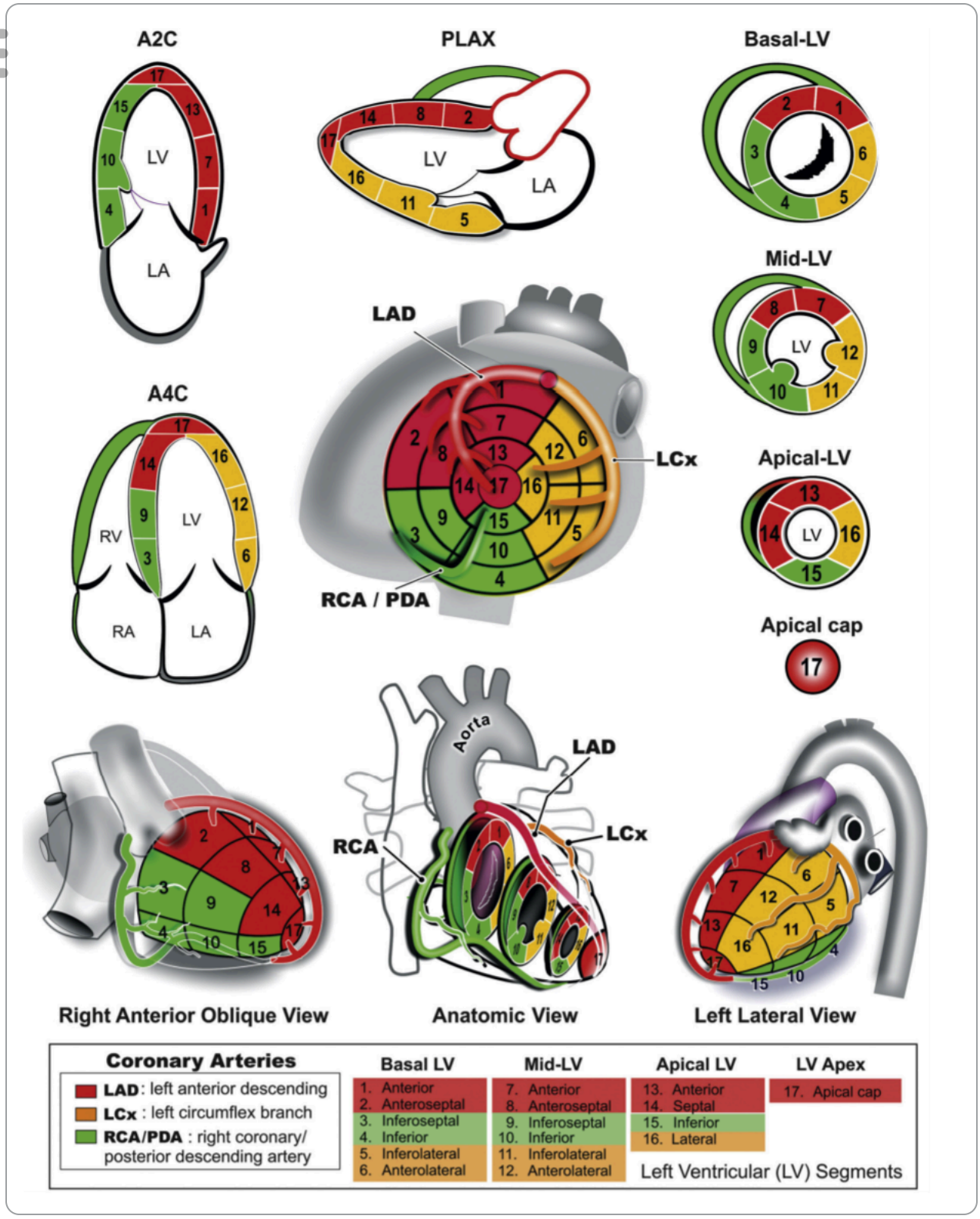

Coronary Artery Territories (Echocardiography Illustrated Book 4)

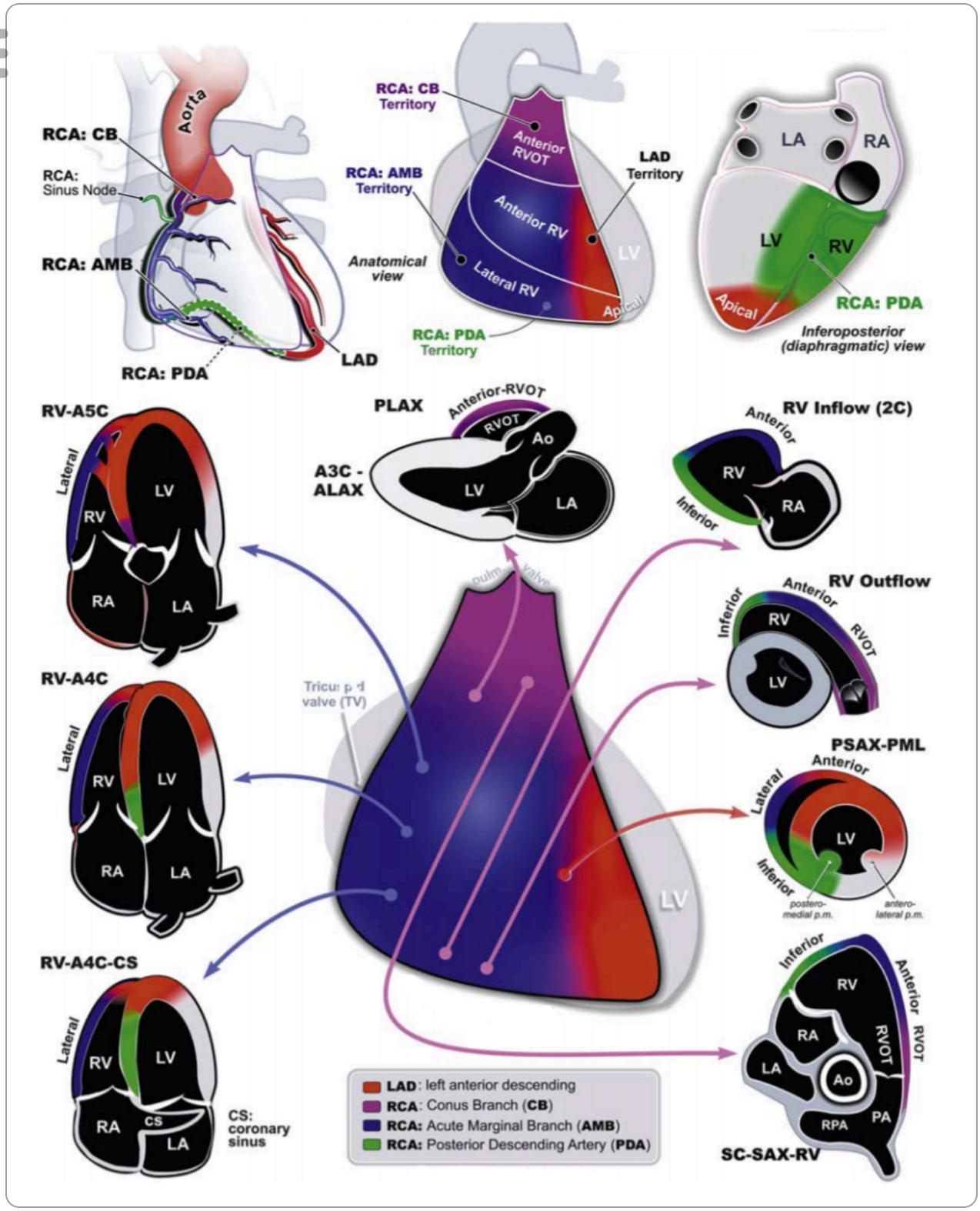

ESSENTIAL ECHOCARDIOGRAPHY A Companion to Braunwald's Heart Disease

Atria

Left atrium (Size)		
	Female	Male
LA AP (cm) Left atrium anterior-posterior dimension	2,7 - 3,8	3,0 - 4,0
LA AP (cm/m^2) Left atrium anterior-posterior dimension	1,5 - 2,3	1,5 - 2,3

Recommendations for Cardiac Chamber Quantification by Echocardiography in Adults: An Update from the ASE and EACVI (2015)

Left atrium (Volume)								
	Male				Female			
	Normal range	Mildly abnormal	Moderately abnormal	Severely abnormal	Normal range	Mildly abnormal	Moderately abnormal	Severely abnormal
LA volume (ml/m^2) Left atrial volume (Biplane)	16 - 34	35 - 41	42 - 48	>48	16 - 34	35 - 41	42 - 48	>48

Recommendations for Cardiac Chamber Quantification by Echocardiography in Adults: An Update from the ASE and EACVI (2015)

Right atrium (Size)	
Variable	Abnormal
RA major (mm) Right atrium major axis dimension	>53
RA minor (mm) Right atrium minor axis dimension	>44
RA area (cm^2) Right atrial area	>18

Recommendations for Cardiac Chamber Quantification by Echocardiography in Adults: An Update from the ASE and EACVI (2015)

Right atrium (Size, Volume)		
	Male	Female
RA major (cm/m^2)	2,4 ±0,3	2,5 ±0,3

Right atrium major axis dimension		
RA minor (cm/m^2) Right atrium minor axis dimension	1,9 ±0,3	1,9 ±0,3
RA volume (ml/m^2) Right atrium volume (Single plane)	25 ±7	21 ±6

Recommendations for Cardiac Chamber Quantification by Echocardiography in Adults: An Update from the ASE and EACVI (2015)

Right atrium (Pressure)				
	Normal **3mmHg** **(0 - 5mmHg)**	**Intermediate** **8mmHg** **(5 - 10mmHg)**	**Intermediate** **8mmHg** **(5 - 10mmHg)**	**High** **15mmHg** **(10 - 20mmHg)**
$IVC_{diameter}$ Inferior vena cava diameter	<2,1cm	<2,1cm	>2,1cm	>2,1cm
$IVC_{collaps}$ Inferior vena cava collapsibility	>50%	<50%	>50%	<50%

Recommendations for Cardiac Chamber Quantification by Echocardiography in Adults: An Update from the ASE and EACVI (2015)

Pericardial effusion

Pericardial effusion (Quantification)		
Small	<1mm	300ml
Moderate	10 - 20mm	500 - 700ml
Large	>20mm	>700ml
Very large	>30mm	Compression

Inferior vena cava

Inferior vena cava (Size)

Variable	Abnormal
$IVC_{diameter}$ Inferior vena cava diameter	>2,1cm

Recommendations for Cardiac Chamber Quantification by Echocardiography in Adults: An Update from the ASE and EACVI (2015)

Aorta

Aorta (Size)		
	mm	mm/m^2
AoA Aortic annulus diameter	20 - 31	13 ± 1
AoSV Aortic sinuses of valsalva diameter	29 - 45	19 ± 1
AoSTJ Aortic sinotubular junction diameter	22 - 36	15 ± 1
AoPxA Proximal ascending aorta diameter	22 - 36	15 ± 2
AoArch Aortic arch diameter	22 - 36	
AoDesc Descending aorta diameter	20 - 30	

Echocardiography in aortic diseases: EAE recommendations for clinical practice (2010)

Aortic valve

Aortic stenosis				
	Aortic sclerosis	Mild	Moderate	Severe
Vmax AoV (m/s) Aortic valve maximum velocity	≤2,5	2,6 - 2,9	3,0 - 4,0	≥4,0
meanPG AoV (mmHg) Aortic valve mean pressure gradient		<20	20 - 40	≥40

AVA (cm^2) Aortic valve area (continuity equation)		>1,5	1,0 - 1,5	<1,0
AVA (cm^2/m^2) Aortic valve area (continuity equation)		>0,85	0,60 - 0,85	<0,60
Velocity ratio Aortic valve velocity ratio (Dimensionless index)		>0,5	0,25 - 0,5	<0,25

Recommendations on the Echocardiographic Assessment of Aortic Valve Stenosis: A Focused Update from the EACVI and the ASE (2017)

Aortic regurgitation

	Mild	Moderate		Severe
Structural parameters				
Aortic leaflets	Normal or abnormal	Normal or abnormal		**Abnormal/flail, or wide coaptation defect**
Left ventricle (Size)	**Normal**[1] (LVEDV ≤150ml male, ≤106ml female)	Normal or mild dilated		Usually dilated[2] (LVEDV >150ml male, >106ml female)
Qualitative doppler				
$RegJet_{widht}$ Regurgitation jet witdh	**Small in central jets** (Width in LVOT <25%)	Intermediate		**Large in central jets**; variable in eccentric jets (Width in LVOT >65%)
Flow convergence (PISAr)	**None or very small** (<0,3cm)	Intermediate		**Large** (≥1cm)
$RegJet_{density}$ Regurgitant jet density (CW doppler)	**Incomplete or faint**	Dense		Dense
PHT_{RegJet}[3] Pressure half time of regurgitant jet	Incomplete or faint Slow (>500ms)	Medium (200-500ms)		**Steep** <200ms
Diastolic reversal flow in descending aorta (PW doppler)	**Brief, early diastolic reversal**	Intermediate		**Prominent holodiastolic reversal**
Semiquantitative parameters[4]				
VCW (cm) Vena contracta width	<0,3	0,3 - 0,6		>0,6
$RegJet_{width\ in\ LVOT}$ (%) Regurgitation jet width in LVOT (centrel jets)	<25	25-45	46-64	≥65

$CSA_{RegJet\ in\ CSA\ LVOT}$ (%) Regurgitation jet CSA in LVOT CSA (centrel jets)	<5	5-20	21-59	≥60
Quantitative parameters[4]				
	Grade I	**Grade II**	**Grade III**	**Grade IV**
EROA (cm^2) Effective regurgitant orifice area	<0,1	0,1 - 0,19	0,2 - 0,29	≥0,3
RegVol (ml) Regurgitant volume of aortic regurgitation	<30	30 - 44	45 - 59	≥60
RF (%) Regurgitant fraction of aortic valve	<30	30 - 39	40 - 49	≥50

- Bolded qualitative and semiquantitative signs are considered specific for their AR grade. Color Doppler usually performed at a Nyquist limit of 50-70 cm/sec.

1. Unless there are other reasons for LV dilation.
2. Specific in normal LV function, in absence of causes of volume overload. Exception: acute AR, in which chambers have not had time to dilate.
3. PHT is shortened with increasing LV diastolic pressure and may be lengthened in chronic adaptation to severe AR.
4. Quantitative parameters can subclassify the moderate regurgitation group.

ASE Recommendations for Noninvasive Evaluation of Native Valvular Regurgitation (2017)

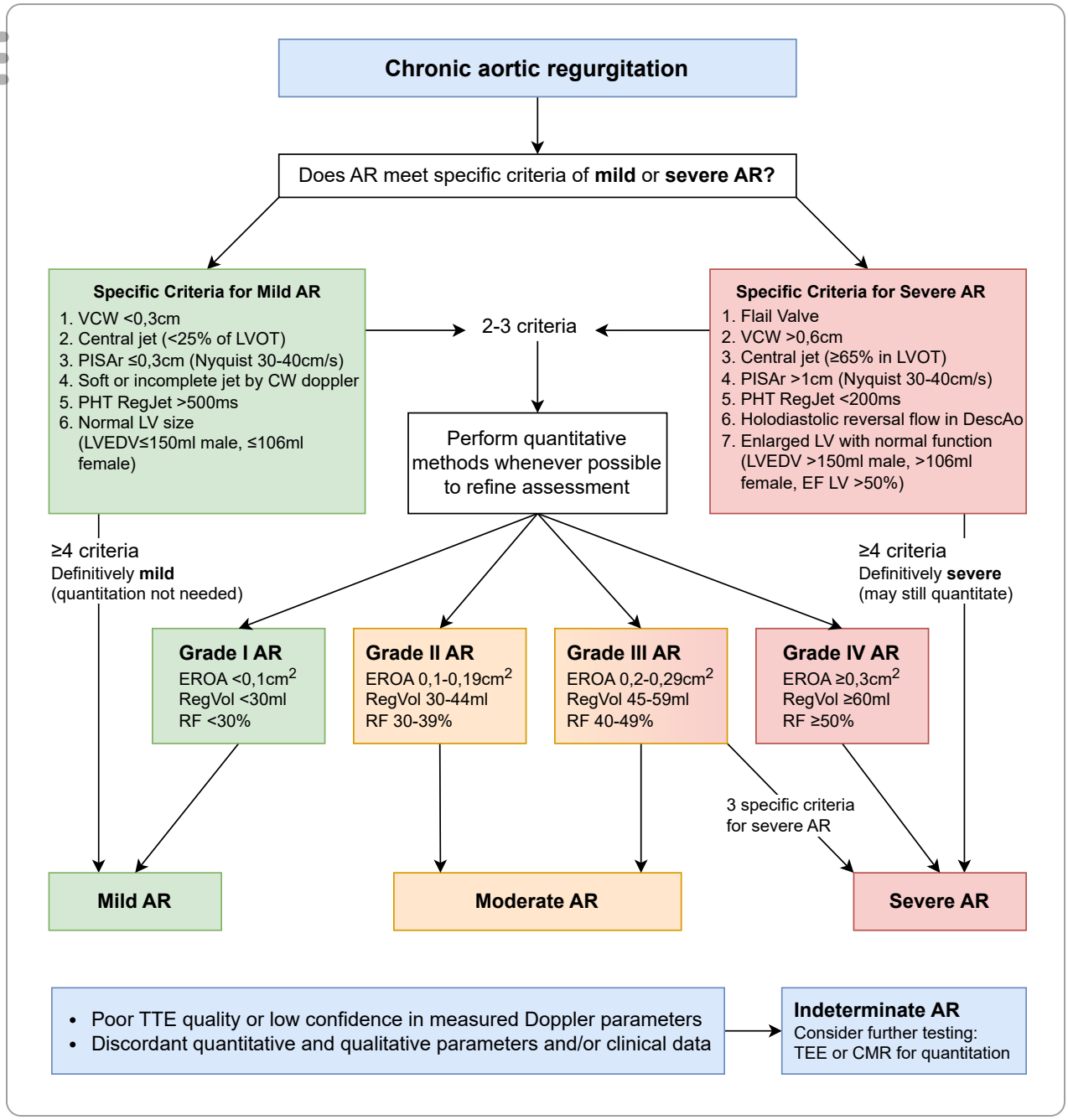

ASE Recommendations for Noninvasive Evaluation of Native Valvular Regurgitation (2017)

Mitral valve

Mitral stenosis			
	Mild	Moderate	Severe
MVA (cm^2)* Mitral valve area	>1,5	1 - 1,5	<1

meanPG MV (mmHg) Mitral valve mean pressure gradient	<5	5 - 10	>10
RVSP$_{(SPAP)}$ (mmHg) Right ventricular systolic pressure	<30	30 - 50	>50

***** Specific findings

Echocardiographic assessment of valve stenosis: EAE/ASE recommendations for clinical practice (2009)

Chronic mitral regurgitation			
	Mild	**Moderate**	**Severe**
Structural			
Mitral valve morphology	**None or mild leaflet abnormality** (e.g., mild thickening, calcifications or prolapse, mild tenting)	Moderate leaflet abnormality or moderate tenting	**Severe valve lesions** (primary: flail leaflet, ruptured papillary muscle, severe retraction, large perforation; secondary: severe tenting, poor leaflet coaptation)
Left ventricle (Size)[1]	Usually normal (LVEDV ≤150ml male, ≤106ml female)	Normal or mild dilated	Dilated[2] (LVEDV >150ml male, >106ml female)
Left atrium (Size)[1]	Usually normal (LA volume ≤34ml/m^2)	Normal or mild dilated	Dilated[2]
Qualitative doppler			
RegJet$_{area}$ Regurgitation jet area. (Nyquist limit 50-70cm/s)	**Small, central, narrow, often brief** (RegJet/LA area <20%)	Variable	Large central jet (RegJet/LA area >50%) or eccentric wall-impinging jet of variable size
Flow convergence (PISAr) (Nyquist limit 30-40cm/s)	**Not visible, transient or small** (PISAr <0,3cm)	Intermediate in size and duration	**Large throughout systole** (PISAr ≥1cm)
Regurgitant jet (CW doppler)	Faint/ partial/ parabolic	Dense but partial or parabolic	Holosystolic/ dense/ **triangular**
Semiquantitative			
VCW (cm) Vena contracta width	<0,3cm	0,3 - 0,7cm	>0,7cm (>0,8cm)[3]
Pulmonary vein flow[4]	**Systolic dominance** (may be blunted in LV dysfunction or AF)	Normal or systolic blunting	Minimal to no systolic flow/ **systolic flow reversal**
Mitral inflow[5]	**A wave dominant** (A wave > E wave)	Variable	E wave dominant (E wave >1,2m/s)
Quantitative[6]			

	Grade I	Grade II	Grade III	Grade IV
EROA (cm^2) Effective regurgitant orifice area	<0,2	0,2 - 0,3	0,3 - 0,39	≥0,4
RegVol (ml) Regurgitant volume of mitral regurgitation	<30	30 - 44	45 - 59	≥60
RF (%) Regurgitant fraction of mitral valve	<30	30 - 39	40 - 49	≥50

- Bolded qualitative and semiquantitative signs are considered specific for their MR grade.
- All parameters have limitations, and an integrated approach must be used that weighs the strength of each echocardiographic measurement. All signs and measures should be interpreted in an individualized manner that accounts for body size, sex, and all other patient characteristics.

1. This pertains mostly to patients with primary
2. LV and LA can be within the “normal” range for patients with acute severe MR or with chronic severe MR who have small body size, particularly women, or with small LV size preceding the occurrence of MR.
3. For average between apical two- and four-chamber views (Biplane).
4. Influenced by many other factors (LV diastolic function, atrial fibrillation, LA pressure).
5. Most valid in patients >50 years old and is influenced by other causes of elevated LA pressure.
6. Discrepancies among EROA, RF, and RegVol may arise in the setting of low or high flow states. Quantitative parameters can help subclassify the moderate regurgitation group.

ASE Recommendations for Noninvasive Evaluation of Native Valvular Regurgitation (2017)

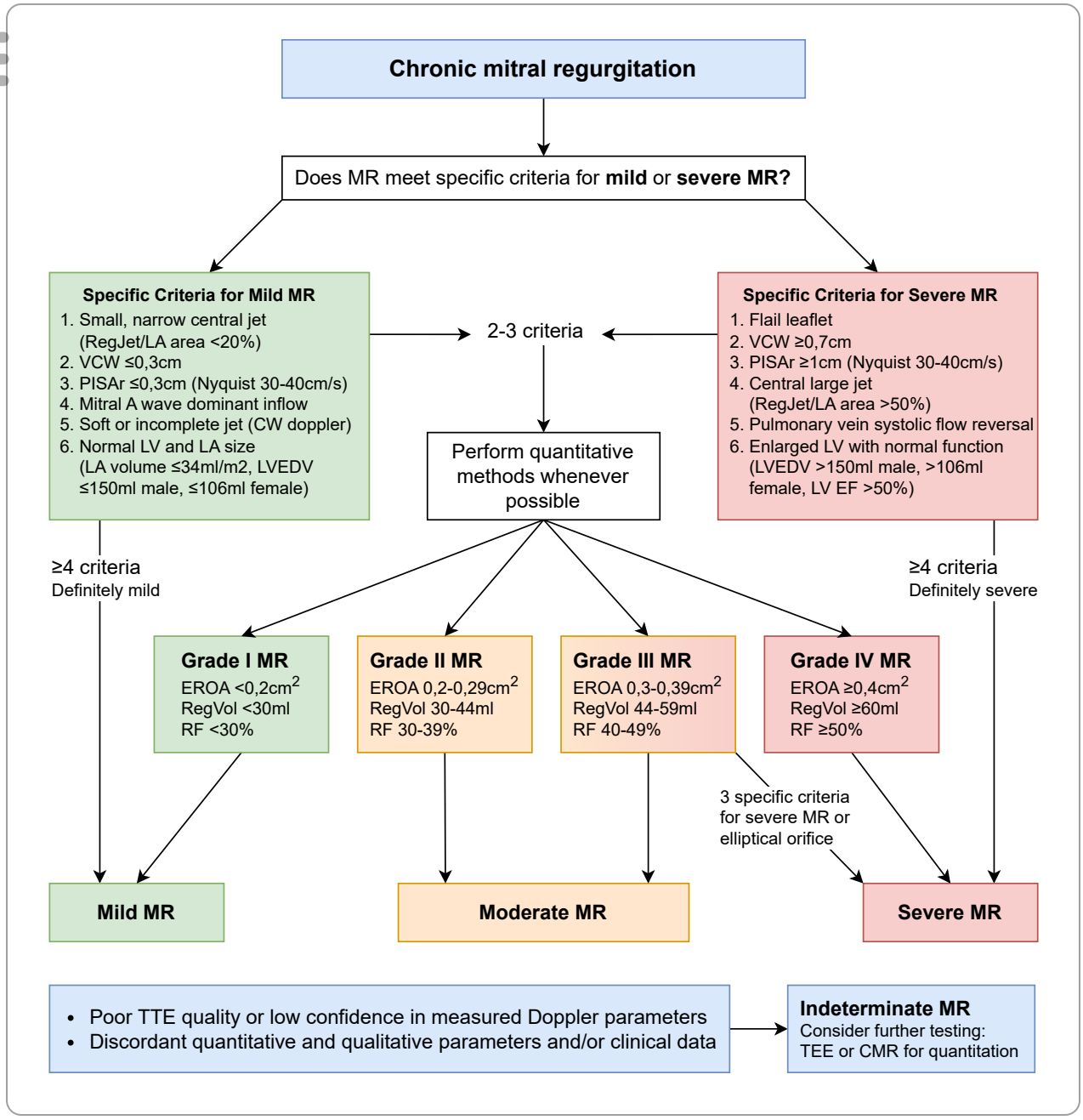

ASE Recommendations for Noninvasive Evaluation of Native Valvular Regurgitation (2017)

Tricuspid valve

Tricuspid stenosis	
Variable	**Abnormal**
meanPG TrV* Mean pressure gradient tricuspidal valve	≥5mmHg

VTI TrV* Velocity time integral of tricuspid valve (inflow)	>60cm
PHT TrV* Pressure half time of tricuspidal valve	≥190ms
TrVA* Tricuspid valve area (continuity equation)	≤1cm^2
RA major Right atrium major axis dimension	>50mm
IVC$_{diameter}$ Inferior vena cava diameter	>2,1cm

* Specific findings

Echocardiographic assessment of valve stenosis: EAE/ASE recommendations for clinical practice (2009)

Chronic tricuspid regurgitation			
	Mild	**Moderate**	**Severe**
Structural			
Tricuspid valve morphology	**Normal or mildly abnormal leaflets**	Moderately abnormal leaflets	**Severe valve lesions** (e.g., flail leaflet, severe retraction, large perforation)
Right atrium (Size)	Usually normal (RA major <45mm)	Normal or mild dilatation	Usually dilated[1] (RA major >45mm)
Right ventricle (Size)	Usually normal (RVD1$_{basal}$ <41mm)	Normal or mild dilatation	Usually dilated[1] (RVD1$_{basal}$ >41mm)
IVC$_{diameter}$ Inferior vena cava diameter	Normal (IVC$_{diameter}$ <2cm)	Normal or mildly dilated (IVC$_{diameter}$ 2,1 - 2,5cm)	Dilated (IVC$_{diameter}$ >2,5cm)
Qualitative doppler			
RegJet$_{area}$ Regurgitation jet area. (Nyquist limit 50-70cm/s)	**Small, narrow, central** (RegJet/RA area <20%)	Moderate central	**Large central jet** (RegJet/RA area >50%) or eccentric wall-impinging jet of variable size
Flow convergence (PISAr) (Nyquist limit 30-40cm/s)	**Not visible, transient or small** (PISAr <0,3cm)	Intermediate in size and duration	**Large throughout systole** (PISAr ≥1cm)
Regurgitant jet (CW doppler)	**Faint/ partial/** parabolic	Dense but partial or parabolic	Dense, often triangular
Semiquantitative			
RegJet$_{area}$ (cm^2) Regurgitation jet area (Nyquist limit 50-70cm/s)	Not defined	Not defined	**>10**

VCW (cm) Vena contracta width (Nyquist limit 50-70cm/s)	<0,3	0,3 - 0,69	**≥0,7**
PISAr (cm) (Nyquist limit 30-40cm/s)	≤0,5	0,6 - 0,9	**>0,9**
Hepatic vein flow[2]	Systolic dominance	Systolic blunting	**Systolic flow reversal**
Tricuspid inflow[2]	**A wave dominant** (A wave > E wave)	Variable	E wave (E wave >1m/s)
Quantitative			
EROA (cm^2) Effective regurgitant orifice area	<0,2	0,2 - 0,39[3]	**≥0,4**
RegVol (ml) Regurgitant volume of tricuspid regurgitation	<30	30 - 44[3]	≥45

- Bolded signs are considered specific for their tricuspid regurgitation grade.

1. RV and RA size can be within the “normal” range in patients with acute severe TR.
2. Signs are nonspecific and are influenced by many other factors (RV diastolic function, atrial fibrillation, RA pressure).
3. There are little data to support further separation of these values.

ASE Recommendations for Noninvasive Evaluation of Native Valvular Regurgitation (2017)

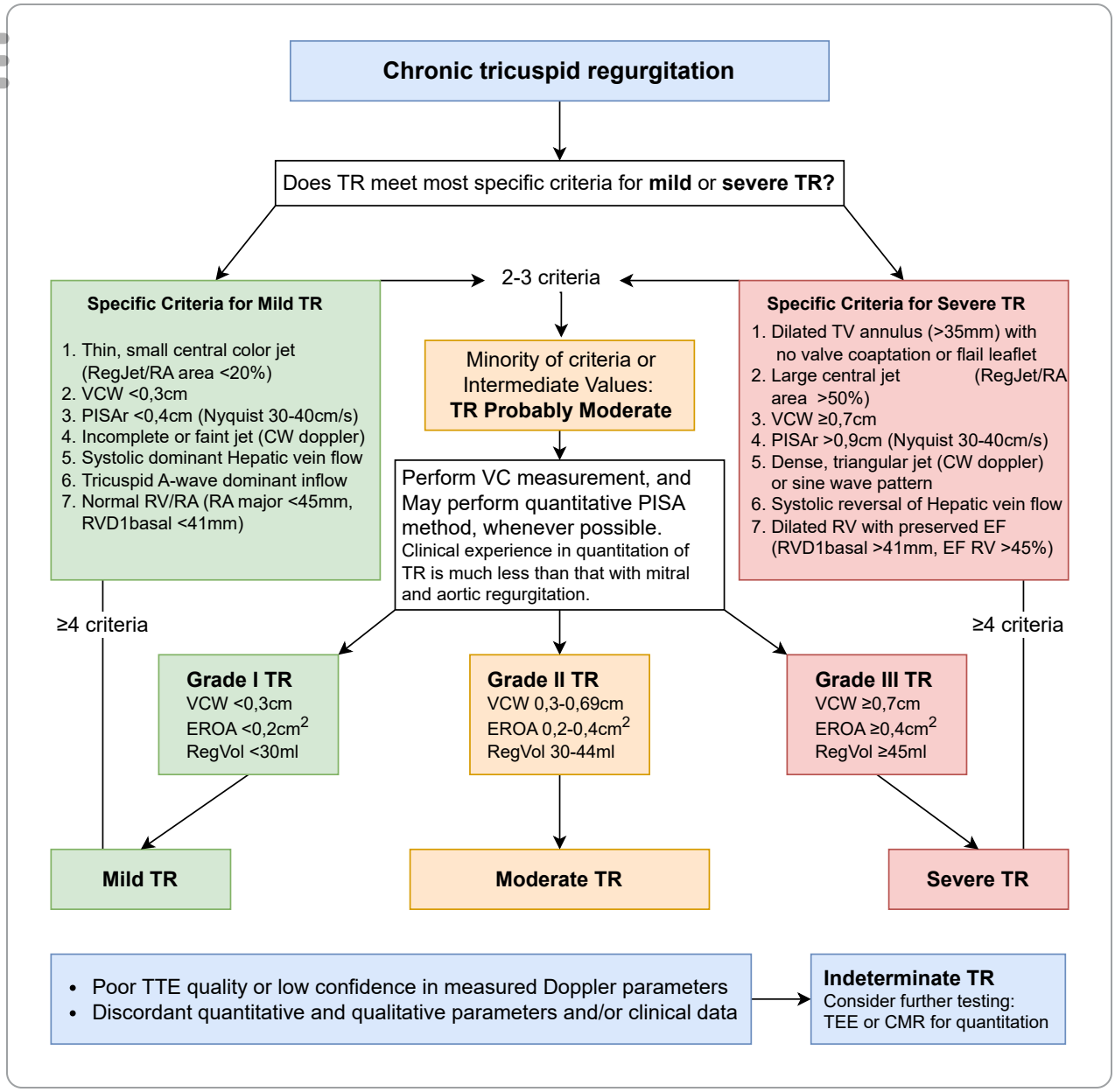

ASE Recommendations for Noninvasive Evaluation of Native Valvular Regurgitation (2017)

Pulmonary valve

Pulmonary stenosis			
	Mild	Moderate	Severe
Vmax PV (m/s) Maximal (peak) velocity pulmonary valve	<3	3 - 4	>4
maxPG PV (mmHg)	<36	36 - 64	>64

Pulmonary valve maximal pressure gradient			

Echocardiographic assessment of valve stenosis: EAE/ASE recommendations for clinical practice (2009)

Pulmonary regurgitation

	Mild	Moderate	Severe
Pulmonic valve	Normal	Normal or abnormal	Abnormal and may not be visible
Right ventricle (Size)	Normal[1] (RVD1$_{basal}$ <41mm)	Normal or dilated	Dilated[2] (RVD1$_{basal}$ >41mm)
RegJet$_{length}$ Regurgitant jet length (Nyquist limit 50-70cm/s)	Thin with a narrow origin (usually <10 mm in length)	Intermediate	Broad origin; variable depth of penetration
Ratio$_{RegJet/PV}$ Ratio regurgitant jet width / pulmonary valve annulus			>70%[3]
RegJet$_{density}$ Regurgitant jet density (CW doppler)	Soft	Dense	Dense; early termination of diastolic flow
DT$_{RegJet}$ Deceleration time of pulmonary regurgitant jet			Short[4] (<260ms)
PHT$_{RegJet}$ Pressure half time of pulmonary regurgitant jet			<100ms[5]
PR index[6] Pulmonory regurgitation index		<0,77	<0,77
PA$_{reversal\ flow}$ Reversal flow in the branch pulmonary artery			Yes
PV VTI / LVOT VTI[7] Pulmonic systolic VTI compered to LVOT VTI	Slightly increased	Intermediate	Greatly increased
RF[8] Regurgitant fraction of pulmonary valve	<20%	20-40%	>40%

1. Unless there are other reasons for RV enlargement.
2. Exception: acute PR.
3. Identifies a CMR-derived PR fraction >40%.
4. Steep deceleration is not specific for severe PR.
5. Not reliable in the presence of high RV end diastolic pressure.
6. Defined as the duration of the PR signal divided by the total duration of diastole, with this cutoff identifying a CMR-derived PR fraction > 25%.
7. Cutoff values for regurgitant volume and fraction are not well validated.
8. RF data primarily derived from CMR with limited application with echocardiography.

ASE Recommendations for Noninvasive Evaluation of Native Valvular Regurgitation (2017)

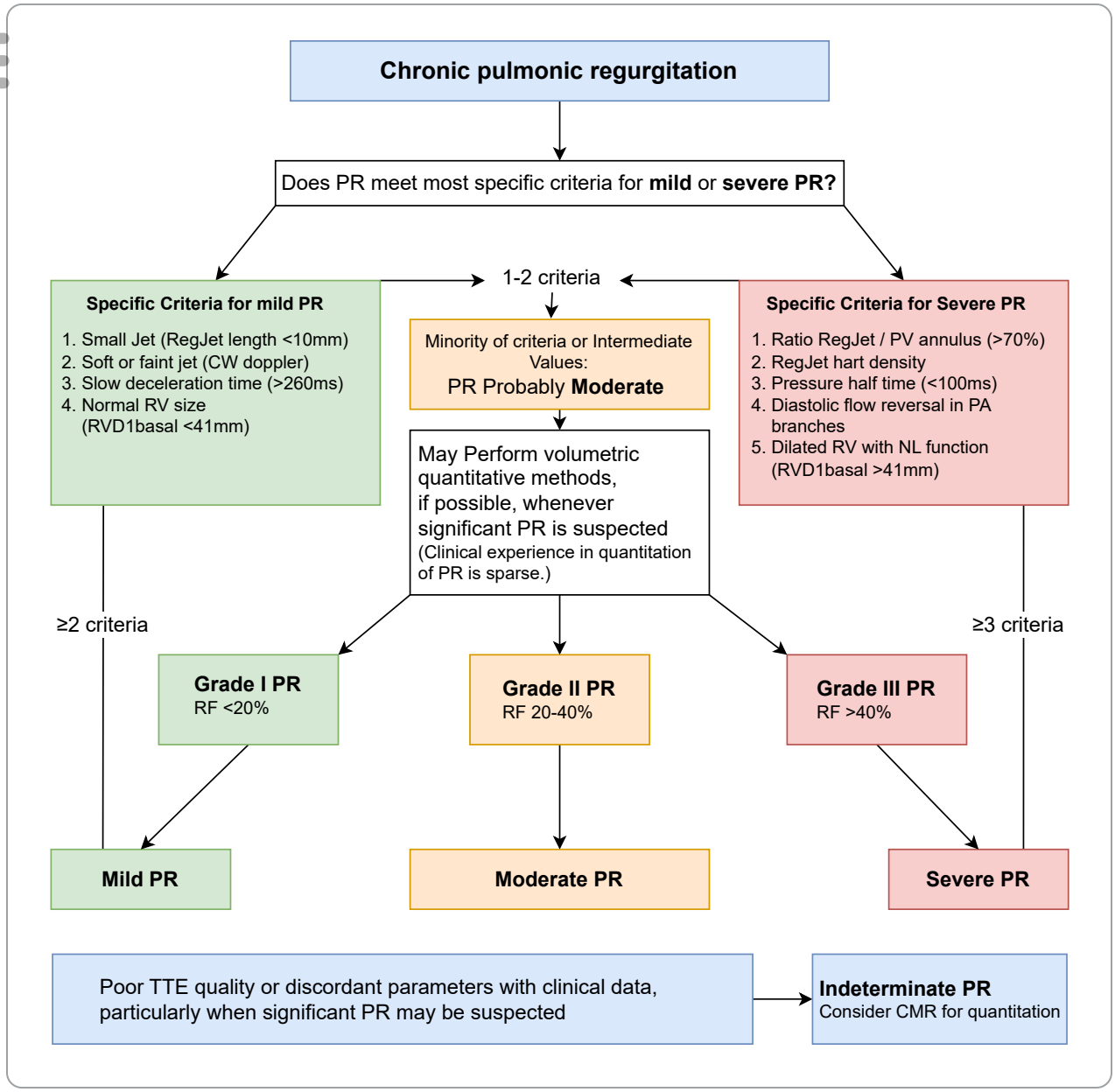

ASE Recommendations for Noninvasive Evaluation of Native Valvular Regurgitation (2017)

References:

Recommendations for Cardiac Chamber Quantification by Echocardiography in Adults: An Update from the ASE and EACVI (2015)

Recommendations for the Evaluation of LV Diastolic Function by Echocardiography: An Update from the ASE and EACVI (2016)

Recommendations on the use of echocardiography in adult hypertension: a report from the EACVI and the ASE (2015)

Recommendations on the Echocardiographic Assessment of Aortic Valve Stenosis: A Focused Update from the EACVI and the ASE (2017)

ASE Recommendations for Noninvasive Evaluation of Native Valvular Regurgitation (2017)

Guidelines for performing a comprehensive TTE examination in adults: Recommendations from the ASE (2018)

Guidelines for the Echocardiographic Assessment of the Right Heart in Adults: ASE, EACVI, ESC, CSE (2010)

Guidelines for the diagnosis and management of acute pulmonary embolism ESC, ERS (2019)

Echocardiography in aortic diseases: EAE recommendations for clinical practice (2010)

Echocardiographic assessment of valve stenosis: EAE/ASE recommendations for clinical practice (2009)

ESSENTIAL ECHOCARDIOGRAPHY A Companion to Braunwald's Heart Disease

Coronary Artery Territories (Echocardiography Illustrated Book 4)